

THE "OBLIQUE KESTENBAUM" PROCEDURE REVISITED (SLOPED RECESSIONS OF THE RECTI)

Annette SPIELMANN

Surgery for nystagmic patients with a head-turn due to the eccentricity of a neutral zone consists in shifting the privileged area in the primary position of gaze. It means conjugate horizontal shift of the eyes in the direction of the head-turn. The procedure associating a recess-resect surgery on each eye is usually called a "horizontal Kestenbaum" from the name of its author.¹

The idea to apply this type of surgery to other head rotations is not new.² As far as a head tilt is concerned the aim of surgery is to create a torsion counter-acting the one which is adopted by the patient: in the case of a head-tilt on the left shoulder as studied in figure 4a, there is a dextrocyclotorsion: excyclotorsion of the right eye, incyclotorsion of the left eye. To create a compensatory levotorsion surgery has to induce an incyclotorsion of the right eye and an excyclotorsion of the left eye. This is what we call in a ridiculous but easy way "an oblique or torsional Kestenbaum".

In 1976 Conrad³ proposed a "torsional Kestenbaum" made of a recess-resect procedure on the torsional anterior fibers of the oblique muscles, sparing the vertically acting posterior fibers of these muscles. Conrad and De Decker⁴ added a transposition of these fibers forwards or backwards to counteract the undesirable vertical effect of this surgery. This is an excellent procedure that I use in extreme torticollis.

At the same time, I proposed two easy procedures for less pronounced torticollis.^{5,6} They can be associated together or with the previous surgery.

- **Recession of the homolateral torsional synergistic muscles:** On one eye a recession of the superior oblique and of the superior rectus induces an excyclotorsion; On the other eye a recession of the inferior oblique and of the inferior rectus induces an incyclotorsion. On each eye the torsional effects add and the vertical actions subtract since those muscles are vertical antagonists. This type of surgery is specially indicated in long standing head-tilts where a vertical imbalance comes from vertical muscle contractures.

- **Slanting of the insertions** of the internal and external recti is the initial procedure to which I added⁷ a slanting of the insertions of the vertical recti (figure 1). This is a kind of "oblique" Kestenbaum we are going to study.

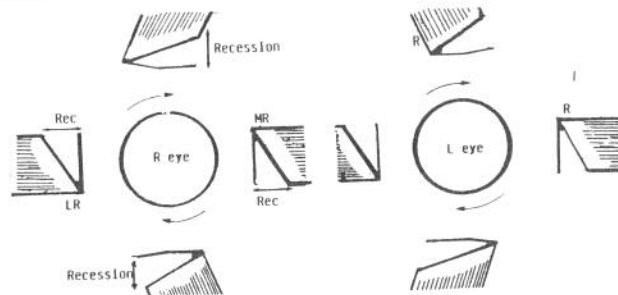


Fig 1- An *incyclotorsion* of the R. eye is created by an oblique recession of the: Inferior fibers of the M.R. -Nasal fibers of the S.R. -Superior fibers of the L.R. -Temporal fibers of the I.R.

An *excyclotorsion* of the L. eye: Superior fibers of the M.R. -Temporal fibers of the S.R. -Inferior fibers of the L.R. -Nasal fibers of the I.R.

The mechanisms of this surgery is understandable when using "montages" easily reproduced at home as we are going to see.

1 - THE SLANTING OF THE INSERTION OF A HORIZONTAL RECTUS has a horizontal action in vertical gaze that we have to cancel and a rotatory action in the primary position that we have to take advantage of.

a) Horizontal effect: (figure 2), in downward gaze the inferior fibers of superior rectus are the ones which are efficient. A recession of the stretched superior fibers of a medial rectus is then followed by an exodeviation in downward gaze, a recession of the inferior fibers of the lateral rectus by an esodeviation in upward gaze. It is in total contradiction with what we were advised to do in alphabetic patterns). When they are performed, a V desequilibrium may occur. In the suggested surgical procedure the medial rectus inferior fibers recession causes an exodeviation in upward gaze; It is counteracted by the recession of the lateral rectus inferior fibers of the other eye which causes an upward esodeviation. Subsequently this procedure is not followed by a horizontal desequilibrium in vertical gaze.

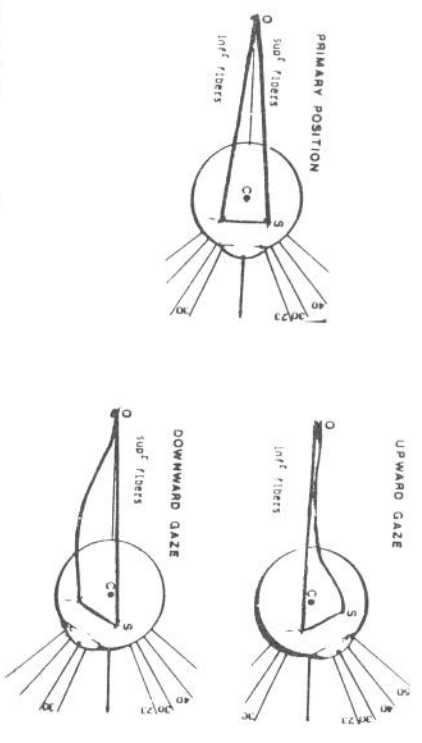


Fig 2.1- The eye is made of a carton device which turns around a pin which is fixed to a sheet of carton through the eye center C. An elastic cord is attached to this globe by means of 2 staples (S) and (I) which correspond to the insertion of the superior (S) and inferior (I) fibers of the muscle. The elastic is attached on the carton behind the globe at (l) which represents the orbital insertion of the muscle. 2-If the eye is moved upwards we can see that the superior fibers of the muscle (0-S) are unstretched and therefore inefficient. 3-If the eye is moved downwards, we can see that the inferior fibers of the muscle (0-I) are unstretched and therefore inefficient.

b) Cyclotorsional effect: as seen on figure 3, a recession of the superior fibers of the medial recti and of the inferior fibers of the lateral vertical meridian of the eyes, that is an **excyclotorsion**. An oblique resection on the same muscle is followed by the same torsional effect as long as we conserve the same obliqueness: a resection of the inferior fibers of the medial rectus has the same torsional effect as a recession of

the temporal fibers of the superior rectus and the nasal fibers of the inferior rectus are stretched. Their traction counterbalance the torsional effect of surgery and may create vertical imbalances. The best way to avoid this iatrogenic action is then to recess these fibers. It adds to the torsional effect and prevents vertical motor imbalances from happening. Finally, a surgical excyclotrotation of the eyes may be created by a recession of the superior fibers of a medial rectus, +/- a recession of the temporal fibers of the superior rectus, of the inferior fibers of the lateral recti, of the nasal fibers of the inferior rectus.

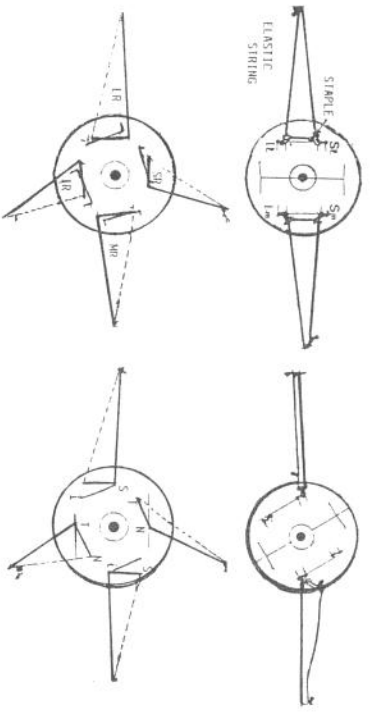


Fig 3 1) The elastic representing the superior fibers of the lateral rectus and of the medial rectus are attached in S_l, S_m and the inferior fibers in I_l and I_m by means of a staple.

2) If the staple S_m and the staple I_l are removed an excyclotrotational movement takes place.

3) During this excyclotrotation of the globes, the temporal fibers of the superior rectus (TS) and the nasal fibers (NI) of the medial rectus are stretched. This opposes rotational movement and may give rise to a vertical deviation. They also have to be recessed.

4) Finally at the end of a successful surgery, the muscles insertions should be aligned as normal ones. We can imagine we have detached the muscles, cyclo-rotated the globe of the wanted amount and then reinserted the muscles at the same place they were before. This would mean also a lateral displacement of the vertical recti and a vertical displacement of the horizontal recti. This we cannot afford. The whole muscle cannot be desinserted because of the anterior chamber vascularization.

We may object that any theory related to partial surgery is still controversial whether relating to horizontal or oblique muscles, because our knowledge of the action of the different fibers of a muscle is still unclear. For instance, as stressed by Bicas¹⁰, the classical theory states that what is important is the physiologic not the anatomic insertion. As the muscle does not slide freely over the scleral surface, therefore all of what has been previewed may be simply reversed in practice. Finally, the best way to consider this surgery is to imagine that we detach the muscles, cyclo-rotate the globe, then reattach the muscles in the same position they were before (figure 4). This gives an idea

to a 15° rotation of an eye. When we need a larger effect, we may increase the amount of surgery or combine it with surgery on the anterior fibers of the oblique muscles.

2 - THE "OBLIQUE KESTENBAUM" PROCEDURE then consists of creating an exocyclorotation of one eye and an incyclorotation of the other eye by the proper slanting of the 8 recti.

a) Example: a typical indication is illustrated in the following case. This 7 year old boy was sent to me for a huge head-tilt with a congenital rotatory nystagmus and light ocular albinism (translumination test +). A 30° to 40° head-tilt on the left shoulder (exycycloposition, of the right eye and incycloposition of the left eye) was still present at the distance and at near.

I performed a slanting of the four recti (fig.1): 7 millimeters of the more recessed part of the muscles. Surgery suppressed most of the head-tilt. It was possible to quantify the result by the following:

- 1-Before surgery, an oblique astigmatism was present as checked by ophthalmoscopy and with a Javal ophthalmometer: 175° - 2 on the right eye, 175° - 3 on the left eye.
- 2-Before starting surgery, I placed a colored vicryl at the limbus at 12 o'clock and 6 o'clock position (figure 4b).
- 3-At the end of the surgery, a torsion of the eyes of approximately 15° had been obtained as shown by the position of the thread.
- 4-The day after surgery, the 15° rotation of the thread was still present and the rotation was confirmed by the change in the axis of the astigmatism which had become 160° - 2 and 160° - 3.

The slanting of the insertions of the 4 recti (7 mm at its greatest) had thus a 15 degree torsional effect on the eyes and corrected a 40 degree head-tilt.

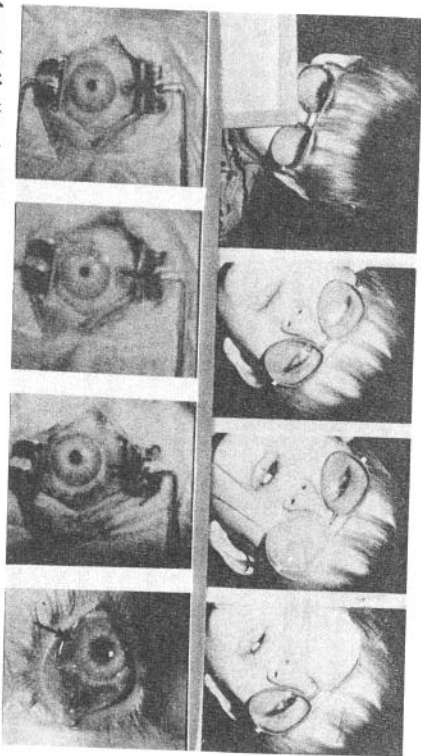


Fig 4a et 4b-Head-tilt at near and at distance. During surgery, a violet vicryl thread had been placed at the 12 o'clock and at 6 o'clock position at the limbus. The induced incyclorotation of the eye is brought into evidence by the position of the thread (175° and 175°) after surgery.

b) Technical dangers: we have to spare a maximum of the ciliary vessels to allow a correct vascularisation of the anterior chamber. One third of the muscles is left attached to the insertion to preserve the ciliary vessels as much as we can. Tucking of the muscle are preferred to resections.

of the oblique muscles. In fact, as stressed by Conrad and De Decker those torsional procedures may be used in any case of torsional disequilibrium whatever its origin and the direction of the nystagmus.

d) Associations: A slanting of the insertions of the horizontal and vertical recti may be associated to a horizontal displacement of the eyes, for instance a horizontal Kestenbaum. This combination is indicated for an economical surgery correcting a horizontal and a torsional deviation on the same muscles. It may be combined with surgery on the oblique muscles, with recession of the medial recti in esodeviation and of the superior recti in dissociated vertical divergence.

3 - IN CONCLUSION: In congenital nystagmus with a head-tilt, the slanting of the insertion of the 4 recti on each eye creates a torsional effect which substitutes for the one which is caused by the head-tilt. This procedure, the quantifying of which has to be improved, has not been followed by any horizontal or vertical oculo-motor disequilibrium up to now. It may be easily associated with a horizontal "Kestenbaum procedure". It may correct any abnormal ocular torsion when surgery on the oblique muscles is not possible or is not possible anymore.

I am well aware, despite the fact that the proposed figures are easy to understand and up to now fit the facts that we are still ignorant of the actions of the different part of a muscle when we dissociate them. But, this surgery is easy to perform. It has proved to be efficient on the head-tilt and on the nystagmus as shown on a movie.

REFERENCES

- 1 Kestenbaum A. Nouvelle opération du nystagmus. B.S.O.F. 1953; 6: 599-606.
- 2 Cüppers C. Problem der operativen Therapie des okularen Nystagmus. Klin.Wbl. Augenheilk 1971; 159:145-157.
- 3 Conrad H.G. Umlagerungschirurgie an den obliquen bei komplizierte Zwangshaltungen. In: Freitag Med.Arbeitskreis Schielbehandlung 1976/9. 4 Conrad H.G., De Becker W. Torsional Kestenbaum procedure: evolution of a surgical concept. In: Reinecke R.D. ed. Strabismus II. 1984; 301-314.
- 5 Spielmann A. Le traitement chirurgical du nystagmus. Arch. Ophthalmol. 1977; 12: 751-766.
- 6 Spielmann A. The surgical treatment of nystagmus. The Jerusalem Conference on Impaired Vision in Childhood 1977. Metab. Ophthalmol. 1978; 2:157-163.
- 7 Spielmann A. "Kestenbaum oblique" sur les muscles droits. Technique personnelle. Mars 1986. Bull. let. Mem. Soc. Fr. Ophthalmol. (in press).
- 8 Bicas H.E.A. Estudios de mecanica ocular. II-Analisis de rotaciones oculares. Anq-Bras. Oftalmol. 1981; 44(1): 26-36.
- 9 Scott A.B. Ocular motility. In: records R.E. Physiology of the human and visual system. Hagerstrom, Harper and Row. 1979; 577-642.
- 10 Bicas H.E.A. Personal communication.

RESUME Une cyclorotation peut être obtenue par le recul oblique des muscles droits. Une recession oblique de 8 muscles droits réalise un Kestenbaum oblique. Une recession de 7 mm (une partie du muscle étant attachée pour préserver un contingent de vaisseaux ciliaires) induit une torsion d'environ 15 degrés comme le montrent les variations de position de l'axe d'un astigmatisme ou d'un fil témoin fixé au limbe à 12h et 6h. Le Kestenbaum oblique peut faire disparaître un nystagmus même horizontal (film).