

## **Instructional Course Handout: Surgery For Nystagmus:**

Richard W. Hertle, M.D., F.A.A.O., F.A.C.S., F.A.A.P.  
Chief of Pediatric Ophthalmology  
Director of The Laboratory of Visual and Ocular Motor Physiology  
Children's Hospital of Pittsburgh  
Professor of Ophthalmology and Bioengineering  
The University of Pittsburgh School of Medicine  
Director of Adult Strabismus Service, The UPMC Eye Center  
Pittsburgh, PA

Derek Sprunger, M.D.  
Clinical Assistant Professor of Ophthalmology  
Indiana University School of Medicine  
Department of Ophthalmology  
Section of Pediatric Ophthalmology & Strabismus  
Indianapolis, IN

:

Louis F. Dell'Osso, Ph.D.  
Director of the Daroff-Dell'Osso Ocular Motility Laboratory  
Louis Stokes Cleveland DVA Medical Center and CASE Medical School  
Professor of Neurology and Biomedical Engineering  
Case Western Reserve University Schools of Medicine and Engineering  
Cleveland, OH

## **Introduction**

Eye care professionals are among the most common to evaluate infants and children with involuntary ocular movements, producing anxiety in the medical care provider as well as the family. This is due to the frequent association of nystagmus with strabismus. Nystagmus comes from the Greek word “*nystagmos*”, *to nod, drowsiness* and from “*nystazein*” *to doze; probably akin to Lithuanian “snusti”, also to doze*. It is a rhythmic, involuntary oscillation of one or both eyes. Using the information obtained from a complete history, physical examination, radiographic and oculographic evaluations over two dozen types of nystagmus were organized and classified according to a National Eye Institute supported collaborative effort by interdisciplinary national experts and is called the Classification of Eye Movement Abnormalities and Strabismus (CEMAS)<sup>1</sup>(Table 1). Some forms of nystagmus are physiologic, whereas others are pathologic. Although the nystagmus is typically described by its more easily observable fast (jerk) phase, the salient clinical and pathologic feature is the presence of a slow phase in one or both directions. Thus, clinical descriptions of nystagmus are usually based on the direction of the fast phase and termed horizontal, vertical, or rotary, or any combination of these. The nystagmus may be conjugate or dysconjugate or predominantly pendular or jerky, the former referring to equal velocity to-and-fro movement of the eyes, and the latter referring to the eyes moving faster in one direction and slower in the other. Involuntary ocular oscillations containing only fast phases are “saccadic oscillations and intrusions” and NOT nystagmus (see CEMAS classification). It is well documented that these differences may be difficult, if not impossible, to differentiate clinically. Recent advances in eye movement recording technology have increased its application in infants and children who have clinical disturbances of the ocular motor system<sup>2,3</sup>. Estimates of its incidence range from 1 in 350 to 1 in 6,550<sup>4-6</sup>. It is difficult if not impossible to give accurate prevalence/incidence on all types of nystagmus combined, but it is known that up to 50% of the infantile strabismic population will either have INS or FMNS. This could increase the prevalence of nystagmus up to 0.5% of the population.

## **Etiology**

Although the theoretical neuronal mechanisms of nystagmus are constantly evolving and beyond the scope of this document it is important to state that central ocular motor control areas are primarily responsible for generation of the anomalous ocular motor signal(s). These include the pursuit system, vestibular system and a part of the vestibular nuclei responsible for gaze holding called the “neural integrator.”

The pursuit system, previously thought to have only a dynamic function, provides a major input for fixation stability (e.g., pursuit at “0 velocity” is stable fixation)<sup>7</sup>. The vestibular system maintains a constant resting firing rate that tends to drive the eyes contralaterally. This tendency is counterbalanced by the vestibular system on the opposite side unless the balance is changed by head rotation. The counterbalance is lost with unilateral vestibular damage and the eyes tend to drift toward the affected side. Most forms of acquired nystagmus are due to disease of the vestibular system (centrally or peripherally). Eye movement recordings show various combinations of uniplanar or multiplanar waveforms that may have simple pendular, linear, accelerating or decelerating velocity slow phases<sup>8</sup>.

### **Infantile Nystagmus Syndrome INS (Previously Congenital Nystagmus or “CN”) [INS includes all CN not just “motor”]**

Familiarity with the clinical features of INS is essential. INS is an ocular motor disorder of unknown etiology, which presents at birth or early infancy and is clinically characterized by involuntary oscillations of the eyes (See Table 2 for distinguishing features). INS can occur in association with congenital or acquired defects in the visual sensory system (e.g., albinism, achromatopsia, and congenital cataracts)<sup>4, 13</sup>. The cause and precise mechanism of INS has not been elucidated. Children with this condition frequently present with a head turn, which is used to maintain the eyes in the position of gaze of the null point (point of minimum nystagmus). Head oscillations are common in INS, but are not used as the strategy to improve vision, except in those rare patients with abnormal gain of their vestibulo-ocular reflex. Oscillopsia is almost never present in INS. Accurate and repeatable classification and diagnosis of nystagmus in infancy as INS is best accomplished by a combination of clinical and motility findings; in some cases, the latter are indispensable for diagnosis (Table 2).

In an infant is diagnosed with INS, ocular motility analysis can also be helpful in determining visual status. Analysis of binocular or monocular differences in waveforms and foveation periods reflect development of the afferent visual system. INS may result from a primary defect (e.g., familial X-linked) or ocular motor calibration or from abnormal cross-talk from a defective sensory system to the developing motor system at any time during the motor system’s sensitive period. The primary ocular motor instability underlying INS is the same but its clinical and oculographic expression are idiosyncratically modified by both initial and final developmental integrity of all parallel afferent visual system processes. Visual loss should be highly suspected in any infant or toddler with onset of nystagmus after early infancy, since mild-to-moderate visual loss may not be readily apparent in the preverbal years. If a child with nystagmus has suspected visual loss, but a normal ocular examination, an afferent and neurological system work up is necessary since retinal dysfunction may be detected even in the absence of pigmentary degeneration.

### **Fusion Maldevelopment Nystagmus Syndrome (FMNS) (Previously “Latent/Manifest Latent” Nystagmus)**

FMNS is a benign, jerk nystagmus that begins in early infancy and is easily observed under monocular viewing conditions. It is bilateral and conjugate with the slow phase toward the covered eye, and the fast phase toward the viewing or suppressed eye. Strabismus, usually in the form of esotropia and sometimes very small, is always [ALL eye-movement documented cases had some sort of strabismus] present (Table 3). It may be difficult to distinguish from INS since patients with INS, esotropia, and a “latent” component will appear clinically identical to patients with FMNS (Figures 1 and 2). The only sure way to diagnose FMNS is by ocular motor recordings<sup>4, 5, 10-12, 14</sup>. FMNS can appear to be converted to “pure” latent nystagmus if the strabismus is repaired early in infancy.

With eye-movement recordings, mild FMNS is usually detected in those patients who appear to have only latent nystagmus clinically. The nystagmus simply becomes more prominent when one eye is occluded. True latent nystagmus is uncommon. FMNS tends to damp on adduction, so patients with this condition may present with a head turn

toward the side of the fixating eye. These patients have an “adduction” damping (Alexander’s law) with the fixing eye and not a true “gaze” null position. In addition to causing the head posture, FMNS can cause the patient to have much worse monocular than binocular visual acuity.

### **Spasmus Nutans Syndrome (SNS)**

Spasmus nutans is the third most common “non-acquired” oscillation beginning in infancy and consists of the association of pendular, low-frequency, small-amplitude, dysconjugate oscillations, a head nodding oscillation and a head tilt. This usually becomes less noticeable as the infant becomes a toddler. Unlike INS, the head nodding is purposeful and may result in improvement of vision and decrease in the nystagmus. The characteristic clinical feature of spasmus nutans is the very fine, rapid pendular nature of the nystagmus<sup>15</sup>. It may be horizontal, vertical, or torsional. Tremendous asymmetry is associated with amblyopia of the more involved eye. Spasmus nutans may be a completely benign condition and clinically but not oculo-graphically resolve within 2 years (Table 4). However, tumors of the diencephalon can cause a condition indistinguishable from spasmus nutans. Consequently, neuroimaging or careful monitoring for visual, neurological, or endocrinological decline is essential.

### **Clinical Evaluation**

The goal of the history and physical examination is to determine whether the nystagmus has been present from “birth” (the first few months of life) or acquired later (Tables 5 and 6). Information regarding a family history of neonatal eye disease, the pregnancy, labor, delivery, and growth and development since birth should be sought. Vision-testing procedures assume special importance. The patient’s “*binocular acuity*” should be tested first. Binocular acuity is the “person’s” acuity and monocular acuity is the “eye’s” acuity. These two are often very different in patients with nystagmus. If present, the patient must be allowed to assume their anomalous head posture (AHP) (which is often impossible if a phoropter is being used). Note that this is the patient’s peak acuity and not primary-position acuity unless there is no AHP. During the examination of visual acuity in nystagmus patients with an AHP it is imperative to observe the direction of the posture over a 5-7 minute period. Up to 17% patients with INS (and up to 33% with albinism) will have a periodicity to the direction of their fast phase<sup>16</sup>. This manifests clinically as a changing head posture in the direction of this fast phase.

In older children, a subjective refraction is the foundation for any type of refractive therapy. The best way to do this is to fog the eye not being refracted with only enough extra plus to decrease the vision in that eye 1-3 lines. In many patients with coincidental strabismus (about 50% of the childhood nystagmus population) they can often fix well enough with one eye at a time, and be subjectively aware of this, that no fogging is necessary. In those patients in whom there is a different refraction under cycloplegia, record BOTH subjective and objective refraction for decision making regarding spectacle prescription.

Complete clinical evaluation includes fast-phase direction, movement intensity, conjugacy, gaze effects, convergence effects, and effect of monocular cover. The amplitude, frequency, and direction of the nystagmus in all directions of gaze can be documented with a simple diagram. The clinician can also observe the nystagmus while moving the patient’s head. Evaluation of associated motility systems (e.g., strabismus,

pursuit, saccades, and vestibulo-ocular reflex) can be clinically evaluated and recorded separately. Changes in the character of the nystagmus with convergence or monocular viewing should be noted.

### **Ocular Motility Recordings**

Electrophysiological analysis using precise eye movement recordings have provided a new basis for eye movement abnormality classification, etiology, and treatment. These electrophysiological investigations have impacted eye-movement systems research in much the same way as electrocardiography did in the study of cardiac rhythms. Eye-movement recordings, by convention, display the data during continuous periods of time. Position and velocity traces are clearly marked with up being rightward or upward eye movements and down being leftward or downward eye movements.

### **Treatment**

There are a number of signs and symptoms due to nystagmus that are amenable to treatment (Tables). The first and most obvious is *decreased vision* (“central visual acuity”, “gaze-angle” acuity, near acuity). Correction of significant refractive errors with spectacles and, importantly, contact lenses in children with nystagmus is the single most powerful therapeutic intervention for improving vision and visual function in these patients. Refractive etiologies of decreased “vision” include either one or a combination of conditions, e.g., myopia, hyperopia, astigmatism, and anisometropia. These refractive conditions can contribute significantly to already impaired vision. The second is *an eccentric gaze, convergence null, or adduction “null”*<sup>17-20</sup>. The eccentric-gaze null is due to INS or acquired nystagmus (e.g., chin-down in downbeat nystagmus), the adduction “null” due to FMNS (manifest strabismus with the preferred eye fixing in adduction), convergence damping due to INS, purposive esotropia (not true convergence) due to INS/FMNS (“nystagmus blockage”) and a periodically changing head posture due to asymmetric, (a)periodic alternating nystagmus. The third is *oscillopsia*, which is usually due to either acquired nystagmus or a change in the sensory/motor status of patient with INS; rarely INS patients with a prominent vestibular component will have oscillopsia. Other less common associated signs and symptoms include hypoaccommodation and photophobia. General medical and eye-muscle surgical treatment guidelines are outlined in Tables 7 and 8. The data collected from many surgical studies on these patients supports the hypothesis that surgical manipulation of the extraocular muscles in patients with oculographically diagnosed INS “improves” the oscillation and visual functions<sup>21-24</sup>. Although patients will have absolute improvement in visual acuity, this is in the range of 1–3 Snellen lines. Other “measures” of visual function are improved after surgery, and also contribute to the visual “well-being.” These include: vision in eccentric gaze (gaze-dependent visual acuity), absolute recognition time, and improved depth and breadth of the null zone and binocular field<sup>21-24</sup>. The clinical and electrophysiological consequences of extraocular muscle surgery in patients with INS may be due to interruption of the afferent proprioceptive loop, producing a damped peripheral ocular motor response to the nystagmus signal<sup>25</sup>.

The prognosis of all these ocular oscillations depends on the type of underlying ocular and systemic disease. In general, infantile forms may improve with time unless they are associated with a degenerative ocular or systemic disease. Acquired forms are more visually disturbing and follow the course of the underlying neurologic disease.

## References

1. CEMAS\_Working\_Group. A National Eye Institute Sponsored Workshop and Publication on The Classification Of Eye Movement Abnormalities and Strabismus (CEMAS). In: Richard W. Hertle MD, ed. The National Eye Institute Publications, [www.nei.nih.gov](http://www.nei.nih.gov). The National Institutes of Health, Bethesda, MD: The National Eye Institute, The National Institutes of Health, 2001.
2. Hertle RW, Dell'Osso LF. Clinical and ocular motor analysis of congenital nystagmus in infancy [see comments]. *J Aapos* 1999;3(2):70-9.
3. Dell'Osso LF, van der Steen J, Steinman RM, Collewijn H. Foveation dynamics in congenital nystagmus. I: Fixation. *Doc Ophthalmol* 1992;79(1):1-23.
4. Abel LA. Infantile nystagmus: current concepts in diagnosis and management. *Clin Exp Optom* 2006;89(2):57-65.
5. Gottlob I. Nystagmus. *Curr Opin Ophthalmol* 1998;9(5):32-8.
6. Stang HJ. Developmental disabilities associated with congenital nystagmus. *J Dev Behav Pediatr* 1991;12(5):322-3.
7. Dell'Osso LF, van der Steen J, Steinman RM, Collewijn H. Foveation dynamics in congenital nystagmus. II: Smooth pursuit. *Doc Ophthalmol* 1992;79(1):25-49.
8. Leigh RJ, Das VE, Seidman SH. A neurobiological approach to acquired nystagmus. *Ann N Y Acad Sci* 2002;956:380-90.
9. Dell'Osso LF. Biologically relevant models of infantile nystagmus syndrome: the requirement for behavioral ocular motor system models. *Semin Ophthalmol* 2006;21(2):71-7.
10. Abadi RV, Scallan CJ. Waveform characteristics of manifest latent nystagmus. *Invest Ophthalmol Vis Sci* 2000;41(12):3805-17.
11. Norcia AM. Abnormal motion processing and binocularity: infantile esotropia as a model system for effects of early interruptions of binocularity. *Eye* 1996;10 ( Pt 2):259-65.
12. Dell'Osso LF. Congenital, latent and manifest latent nystagmus--similarities, differences and relation to strabismus. *Jpn J Ophthalmol* 1985;29(4):351-68.
13. Reinecke RD. Costenbader Lecture. Idiopathic infantile nystagmus: diagnosis and treatment. *J Aapos* 1997;1(2):67-82.
14. Abadi RV, Bjerre A. Motor and sensory characteristics of infantile nystagmus. *Br J Ophthalmol* 2002;86(10):1152-60.
15. Weissman BM, Dell'Osso LF, Abel LA, Leigh RJ. Spasmus nutans. A quantitative prospective study. *Arch Ophthalmol* 1987;105(4):525-8.
16. Shallo-Hoffmann J, Riordan-Eva P. Recognizing periodic alternating nystagmus. *Strabismus* 2001;9(4):203-15.
17. Weiss AH, Kelly JP. Acuity development in infantile nystagmus. *Invest Ophthalmol Vis Sci* 2007;48(9):4093-9.
18. Wang ZI, Dell'Osso LF. Being "slow to see" is a dynamic visual function consequence of infantile nystagmus syndrome: model predictions and patient data identify stimulus timing as its cause. *Vision Res* 2007;47(11):1550-60.
19. Hertle RW, Reese M. Clinical contrast sensitivity testing in patients with infantile nystagmus syndrome compared with age-matched controls. *Am J Ophthalmol* 2007;143(6):1063-5.

20. Yang D, Hertle RW, Hill VM, Stevens DJ. Gaze-dependent and time-restricted visual acuity measures in patients with Infantile Nystagmus Syndrome (INS). *Am J Ophthalmol* 2005;139(4):716-8.
21. Hertle RW, Yang D. Clinical and electrophysiological effects of extraocular muscle surgery on patients with Infantile Nystagmus Syndrome (INS). *Semin Ophthalmol* 2006;21(2):103-10.
22. Hertle RW, Dell'Osso LF, FitzGibbon EJ, et al. Horizontal rectus muscle tenotomy in children with infantile nystagmus syndrome: a pilot study. *J Aapos* 2004;8(6):539-48.
23. Hertle RW, Anninger W, Yang D, et al. Effects of extraocular muscle surgery on 15 patients with oculo-cutaneous albinism (OCA) and infantile nystagmus syndrome (INS). *Am J Ophthalmol* 2004;138(6):978-87.
24. Dell'Osso L, Hertle RW, Williams, RW, Jacobs JB. A new study for congenital nystagmus: effects of tenotomy on an achiasmatic canine. *Journal of the American Association for Pediatric Ophthalmology and Strabismus* 1998;In Press(In Press):xxx.
25. Hertle RW, Chan CC, Galita DA, et al. Neuroanatomy of the extraocular muscle tendon enthesis in macaque, normal human, and patients with congenital nystagmus. *J Aapos* 2002;6(5):319-27.

**TABLE 1 – CEMAS Classification Of Nystagmus Types<sup>1</sup>**

<b><u>Classification of Eye-Movement Abnormalities and Strabismus (CEMAS)</u></b> <b><u>Involuntary Ocular Oscillations</u></b>	
1. Peripheral Vestibular Imbalance	➤ Meniere, Drug toxicity
2. Central Vestibular Imbalance	➤ Downbeat, Upbeat, Drug toxicity
3. Instability of Vestibular Mechanisms	➤ Periodic Alternating Nystagmus
4. Disorders of Visual Fixation	➤ Vision Loss, See-Saw Nystagmus, Drug toxicity
5. Disorders of Gaze Holding	➤ Gaze Evoked, Acquired Pendular, Drug toxicity
6. Acquired Pendular Nystagmus	➤ Central myelin, Oculopalatal, Whipple, Drug toxicity
7. Saccadic Intrusions and Oscillations	➤ Square-Wave Jerks, Macro-saccadic oscillations, opsoclonus, flutter, pulses
8. Miscellaneous Eye Movements	➤ Superior Oblique Myokymia, Ocular motor neuromyotonia
9. Infantile Nystagmus Syndrome	➤ “congenital,” “motor,” “sensory,” idiopathic, nystagmus blockage
10. Fusion Maldevelopment Nystagmus Syndrome	➤ Old “Latent/manifest latent,” nystagmus blockage
11. Spasmus Nutans Syndrome	➤ Without optic pathway glioma ➤ With optic pathway glioma

**TABLE 2 – CEMAS Criteria For Infantile Nystagmus Syndrome<sup>1</sup>**

<b>Disease Name</b>	<b>INFANTILE NYSTAGMUS SYNDROME (INS) [Old Congenital Nystagmus and “Motor and Sensory” Nystagmus]</b>
<b>Criteria</b>	Infantile onset, ocular motor recordings show diagnostic (accelerating) slow phases, low-amplitude pendular nystagmus (dual-jerk waveform)
<b>Common Associated Findings</b>	Conjugate, horizontal-torsional, increases with fixation attempt, progression from pendular to jerk, family history often positive, constant, conjugate, with or without associated sensory system deficits (e.g., albinism, achromatopsia), associated strabismus or refractive error, decreases with convergence, exaggerated esotropia (“blockage”), null and neutral zones present, associated head posture or head shaking, may exhibit a “latent” component, “reversal” with OKN stimulus or (a)periodicity to the oscillation. Candidates on Chromosome X and 6. May decrease with induced convergence, increased fusion, extraocular muscle surgery, contact lenses and sedation.
<b>General Comments</b>	Waveforms may change in early infancy, head posture usually evident by 4 years of age. Vision prognosis dependent on integrity of sensory system.

**TABLE 3 – CEMAS Criteria For Fusion Maldevelopment Nystagmus Syndrome<sup>1</sup>**

<b>Disease Name</b>	<b>FUSION MALDEVELOPMENT NYSTAGMUS SYNDROME (FMNS) [Old Latent/Manifest Latent Nystagmus]</b>
<b>Criteria</b>	Infantile onset, associated strabismus, ocular motor recordings show two types of slow phases (linear and decelerating) plus high-frequency, low-amplitude pendular nystagmus (dual-jerk waveform), jerk in direction of fixing eye.
<b>Common Associated Findings</b>	Conjugate, horizontal, uniplanar, Usually no associated sensory system deficits (e.g., albinism, achromatopsia), may change with exaggerated esotropia (“blockage”), head posture associated with fixing eye in adduction, no head shaking, may exhibit “reversal” with OKN stimulus, no (a)periodicity to the oscillation. Dissociated strabismus may be present. Decreases with increased fusion (binocular function).
<b>General Comments</b>	Intensity decreases with age.

**TABLE 4 – Criteria for Neurological Work-Up**

<b>1. HISTORY</b>
a. Onset of nystagmus after 6-9 months of age
b. History of severe prematurely or developmental or genetic diseases
c. Abnormal pregnancy, labor or delivery
d. Abnormal and/or delayed growth
e. Exposure to toxins or drugs
<b>2. OPHTHALMIC EXAMINATION –</b>
a. Abnormal vision of the eye(s) (e.g., photophobia, delayed visual behavior)
b. Abnormal structural examination of the eye(s) (e.g., foveal or optic nerve dysplasia)
c. Nystagmus pattern vertical, asymmetric, dysconjugate or associated with other ocular motor disorders (e.g., decreased pursuit, abnormal saccades, and paretic gaze)
<b>3. GENERAL PEDIATRIC EXAMINATION –</b>
a. Pediatrician is concerned with growth, development or patient has manifest “hard” or “soft” focal or diffuse neurologic signs.

**TABLE 5 – Surgical Treatment of Nystagmus**

<b>Operation 1 - Induced Convergence (Artificial Divergence)</b>
<i>Indication</i> Binocular Function (Stereopsis) With Measurable Foveation Improvement or Observable Convergence Damping
<i>Preparation</i> Prism Adapt With 7 BO Each Eye, Not Fresnell
<i>Technique</i> Bilateral Medial Rectus Recess 3.0 And Bilateral Lateral Rectus Tenotomy With Reattachment
<b>Operation 2 - Eccentric Horizontal Null Position Alone</b>
<i>Indication</i> Measurable or Clinically Observable Eccentric Gaze Null With Head Posture In Opposite Direction
<i>Preparation</i> Rule Out Aperiodic Or Periodic Infantile Subtype, No Changing Posture Over 10 Minutes Of Observation.
<i>Technique</i> A. Recess Lateral Rectus 10.0 In The Abducted Eye And Medial Rectus 7.0 In The Adducted Eye With Tenotomies And Reattachment Of The Other Horizontal Recti For Turns Up To 20 Degrees. B. Recess Lateral Rectus 10.0 In The Abducted Eye And Medial Rectus 7.0 In The Adducted Eye 10.0 And Resect The Medial Rectus 7.0 In The Abducted Eye And Resect The Lateral Rectus 11.0 In The Adducted Eye For Turns Greater Than 20 Degrees. (see Table at end)

**Operation 3 - Torsional Head Posture***Indication*

Torsional Head Posture Alone

*Preparation*

Rule Out Aperiodic Or Periodic Infantile Subtype, No Changing Posture Over 10 Minutes Of Observation.

*Technique*

Horizontal Transposition Of Vertical Recti One Full Tendon Width, (Hint Take The Vertical Recti Off, Move The Eyes In The Direction Of The Head Posture, Reattach The Vertical Recti) I.E., Right Head Tilt, RSREC Nasal, RIREC Temporal, LSREC Temporal, LIREC Nasal.

**Operation 4 – Chin Up Head Posture***Indication*

Chin-Up Head Posture Alone, Nystagmus Changes Intensity In Upgaze

*Preparation*

Rule Out Aperiodic Or Periodic Infantile Subtype, No Changing Posture Over 10 Minutes Of Observation.

*Technique*

Bilateral Superior Oblique 5.0 mm Tenectomy Nasal To The Superior Rectus Plus Bilateral Inferior Rectus 4.0 Recessions

**Operation 5 – Chin Down Head Posture***Indication*

Chin-Down Head Posture Alone, Nystagmus Changes Intensity In Downgaze

*Preparation*

Rule Out Aperiodic Or Periodic Infantile Subtype, No Changing Posture Over 10 Minutes Of Observation.

*Technique*

Bilateral Inferior Oblique Myectomy Plus Bilateral Superior Rectus 4.0 Recessions

**Operation 6 – Head Posture – Nystagmus - Strabismus***Indication*

Head Posture Plus Strabismus

*Preparation*

Rule Out Aperiodic Or Periodic Infantile Subtype Or Esotropia With Fusion Maldevelopment And Adduction Null, I.E., No Changing Posture Over 10 Minutes Of Observation. Determine Fixing Eye (Eye Driving The Head Posture)

*Technique*

Straighten The Head With Prism Correction Over The Preferred Eye, Neutralize The Resulting Strabismic Deviation With Prism Over The Non-Preferred Eye. Perform Bilateral Recess/Resect On Each Eye's Respective Measured Prism Correction or Bilateral Recess Plus Tenotomy With Reattachment On The Remaining Two Horizontal Recti.

**Operation 7 – Multiplanar Head Posture***Indication*

Combination Chin Up/Down And Face Turn

*Preparation*

Rule Out Aperiodic Or Periodic Infantile Subtype Or Esotropia With Fusion Maldevelopment And Adduction Null, I.E., No Changing Posture Over 10 Minutes Of Observation.

*Technique*

Three Muscles Each Eye. Combine Respective Oblique Plus Vertical Recti (Above) For Chin Up/Down With 10.0 Recess Of Lateral Rectus Of Abducting Eye And 7.0 Recess Of Medial Rectus Of Adducting Eye.

**Operation 8 – Nystagmus And Strabismus***Indication*

Nystagmus And Horizontal Strabismus With No Head Posture

*Preparation*

Treat Refractive Errors.

*Technique*

Recess/Resect Of All Four Horizontal Recti For The Total Deviation Or Bilateral Recess For The Total Deviation Plus Tenotomy With Reattachment On The Remaining Two Horizontal Recti.

**Operation 9 – Nystagmus Alone (About 15% Of INS Population)***Indication*INS With Or Without Periodicity And NO Strabismus, Static Anomalous Head Posture Or Fusion With Convergence Damping*Preparation*

Rule Out Strabismus, Static Head Posture Or Convergence Damping

*Technique*

Bilateral Horizontal Recti Tenotomy With Reattachment And, If The Patient Desires Additional Damping, Bilateral Horizontal Rectus Recession (Lateral Recti Recess 10.0 To 12.0 And Bilateral Medial Recess 8.0 To 10.0)

	DEGREE OF RIGHT FACE TURN	LEFT EYE (RECESS LR)	LEFT EYE (RESECT MR)	RIGHT EYE (RECESS MR)	RIGHT EYE (RESECT LR)
<b>CLASSIC PARKS</b>	< 20 Deg	7 mm	6 mm	5 mm	8 mm
	30 Deg	9 mm	8 mm	6.5 mm	10 mm
<b>(+) 40%</b>	45 Deg	10 mm	8.5 mm	7 mm	11 mm
<b>(+) 60%</b>	50 Deg	11 mm	9.5 mm	8 mm	12.5 mm

or

	DEGREE OF RIGHT FACE TURN	LEFT EYE (RECESS LR)	LEFT EYE (RESECT MR)	RIGHT EYE (RECESS MR)	RIGHT EYE (RESECT LR)
<b>FLYNN</b>  <b>(for &lt;10 Deg, 4-muscle Tenotomy)</b>	10 Deg	<1 mm	<1 mm	<1 mm	<1 mm
	15 Deg	2.5 mm	2.5 mm	2.5 mm	2.5 mm
	20 Deg	6.5 mm	6.5 mm	6.5 mm	6.5 mm
	30 Deg	8.5 mm	8.5 mm	8.5 mm	8.5 mm
	45 Deg	9.5 mm	9 mm	9 mm	9.5 mm
	50 Deg	10.5 mm	10 mm	10 mm	10.5 mm

**FIGURE 1 – Eye-Movement Recording of INS with “Latent Component”**

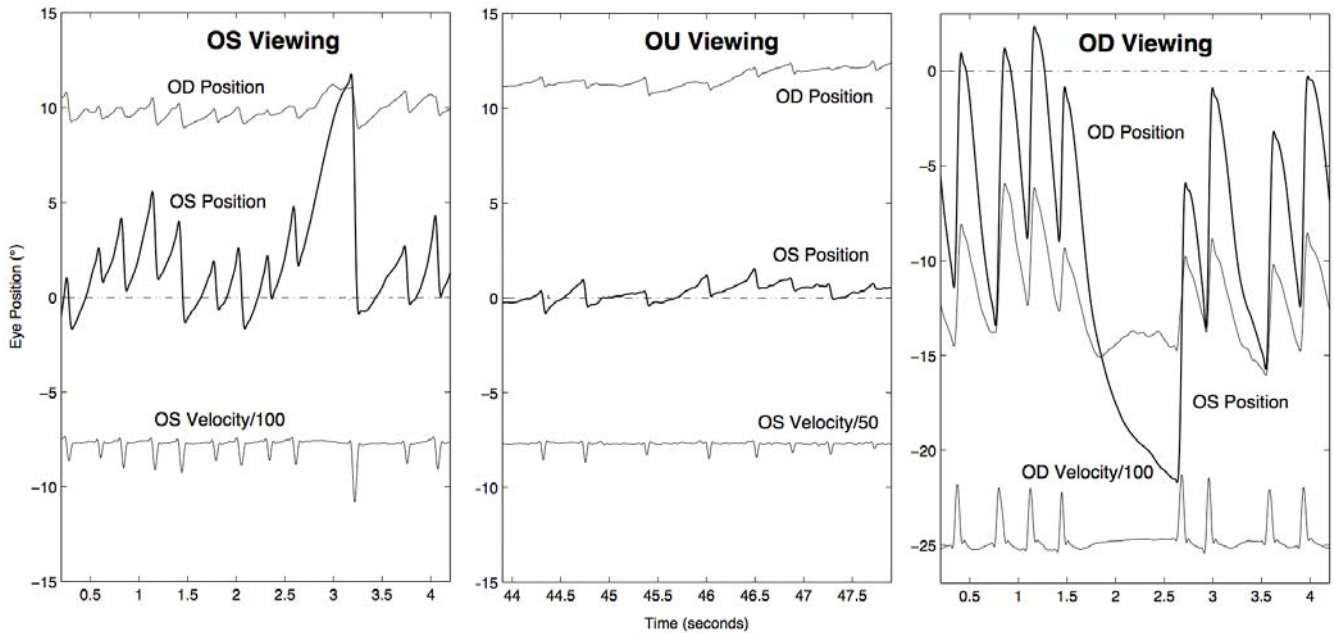


Figure 1 – Eye-movement recordings of patient with infantile nystagmus syndrome and a “latent” component. With OS viewing, the direction is left beating with increasing velocity slow phases (jerk with extended foveation); with OD viewing, there is a change in direction to right beating. With OU viewing, the direction is left-beating, and the waveform has much better foveation periods and much reduced peak-to-peak amplitude. This patient would be clinically indistinguishable from one with fusion maldevelopment nystagmus syndrome. Upward movement in the trace indicates a rightward eye-movement. Bold traces are fixating-eye position traces. The dot-dashed line indicates the target. Velocity traces are scaled and offset for clarity. All three panels have the same x- and y-axis scales to aid comparison of foveation periods and nystagmus amplitudes. Note that in the OS and OD viewing panels there are attention lapses resulting in large-amplitude, slow-phase runaways. (OS=left eye; OU=both eyes; OD=right eye).

**FIGURE 2 – Eye-Movement Recording of FMNS Showing Change with Cover**

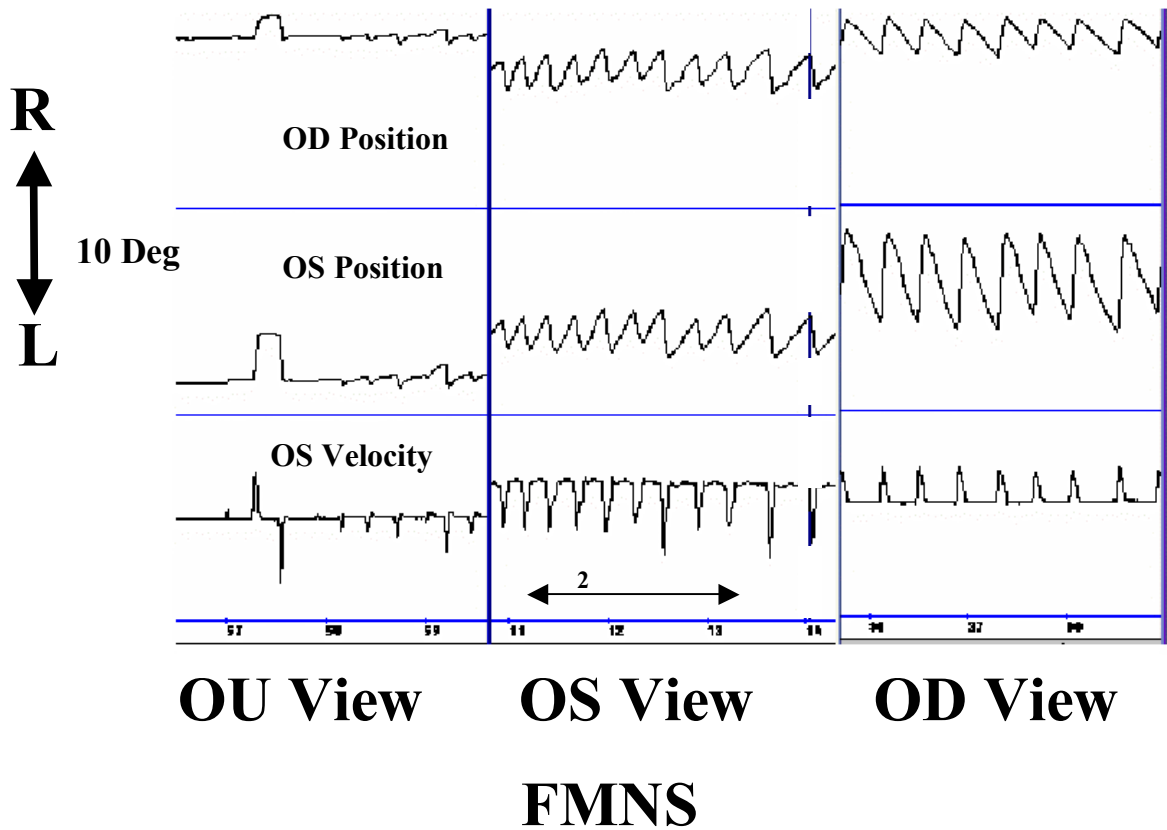


Figure 2 – Eye-movement recording of fusion maldevelopment nystagmus syndrome. With both eyes open, there are small-amplitude, left-beating movements with linear and decreasing velocity slow phases. With the left eye viewing, there is a change in intensity to clinically obvious left-beating nystagmus; with the right eye viewing, the direction changes to more intense right beating nystagmus because this is the non-preferred eye. This patient would be clinically indistinguishable from one with infantile nystagmus syndrome and a “latent” component. (FMNS = fusion maldevelopment nystagmus syndrome, R = right, L = left, OD = right eye, OS = left eye, OU = both eyes, Deg = degrees, Position = eye-position trace, velocity = eye-velocity trace (differentiated eye-position signal) showing direction of fast phases.