

ALUMNI MEETING

9 August 2010

OMC Unit
Logan Mitchell

CASE ONE

- 22 year old male presents to ED 26/4/10
 - 4 day history intermittent binocular vertical diplopia
 - Recent URTI
- POcHx nil
- PMHx
 - L cholesteatoma with mastoidectomy 2007

EXAMINATION

- R hypoglobus 3 mm
- L head tilt (including on driver's licence photo)
- RHT worse L gaze and R head tilt

ASSESSMENT / INVESTIGATION

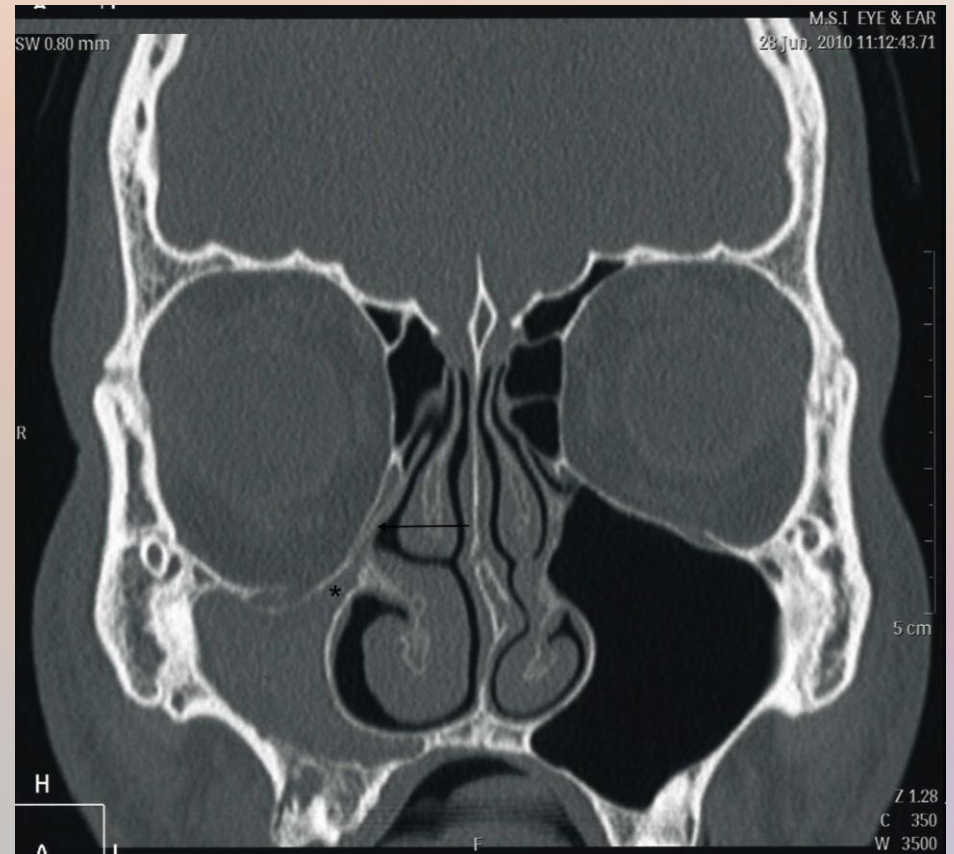
- Likely congenital R CNIV palsy
- MRI brain ordered
 - Normal midbrain anatomy
 - Normal CNIV path
 - No SO muscle belly size difference
 - Normal L:R ratio 95% CI 0.99-1.00 (!!)
 - Incomplete images, but incidental finding of
 - Small R maxillary antrum (opacified), concave orbital floor, inferiorly displaced

PROGRESS

- 21 May 2010 OMC
 - Small R hyperphoria only noted (2-4[^])
 - Worse on L gaze, and up-and-left gaze
 - Slightly worse on L head tilt
 - i.e. equivocal BHTT
 - EOM (see pics)
 - Synoptophore
 - No torsion, no vertical fusion range
 - 3 mm right hypoglobus and enophthalmos

ASSESSMENT / INVESTIGATION

- Referred to OPAL and ENT
 - ENT organised CT orbits
 - Acknowledgement to Philip Michael
- 22 July 2010
 - Right FESS surgery
 - Uncinate removal and



SILENT SINUS SYNDROME


- Painless enophthalmos associated with chronic maxillary atelectasis
 - ~100 described cases, largest series 22
 - Average age at presentation fourth decade (19-82)
 - Diplopia an uncommon presentation
- Aetiology (current thinking):
 - Osteomeatal complex obstruction leads to hypoventilation and negative pressure of maxillary sinus

SILENT SINUS SYNDROME

- Management
 - Surgical
 - Reventilation of sinus
 - (arrests disease progression)
 - +/- orbital reconstructive surgery
 - Usually staged, sometimes combined
 - Reconstruction indicate for cosmesis or diplopia

“SUPERIOR OBLIQUE PALSIES”

- Case demonstrates limited sensitivity of “3-step test” for diagnosing SO palsy
 - ?Better term “Oblique dysfunction resembling SO palsy”
 - Value of orbital imaging
 - Confirming diagnosis if clinically relevant
 - i.e. lack of vertical fusion range and torsion in this case
 - Prognostification
 - Surgical planning



CASE TWO

- Mr DW, unemployed salesman
- Presents GEC with R cataract June 2007, aged 52
 - Gradual history increasing R blur
- POCHx
 - High myopia (-20 R -15 L)
 - R 'macular hole': poor VA ~20 yrs, worse last 5 yrs
 - HLA-B27 recurrent AAU
 - RET ~3 yrs, no mention of diplopia
- PMHx nil

EXAMINATION

June 2007

- VA cc R CF L 6/18
- RET $>50^\circ$ D=N, limitation abduction R>L
- Anterior segment examination NAD
- IOP 12 R 15 L
- Lens R NS+++ L clear
- Fundi myopic degenerative changes R>L
 - Lattice noted R periphery

MANAGEMENT

June 2007

- Advised against R cataract surgery
- Referred VRU re R peripheral changes
 - 2 x R HST: cryopexy July 2007

ED PRESENTATION

November 2007

- 3/7 hx diplopia, fall 1/52 earlier – minor head trauma
 - Diplopia not reproduced on examination
 - Large RET noted
- CT orbits
 - Old R medial wall #
 - (RLR inferiorly displaced)
- Diagnosed “probably heavy eye syndrome”

PROGRESS

- January 2008 GEC
 - F/U of iritis
 - Booked R recess/resect
- February 2008 OMC
 - RET 60[^], RET' 87[^], RLR-
 - No diplopia at angle for near, unable to assess at distance due to poor fixation
 - Synoptophore = no retinal correspondence
 - Axial lengths 31.79 mm R 29.86 mm L
 - Recommendation for bilateral ET surgery on adjustables

PROGRESS

- 18 August 2008 GEC
 - Right medial rectus recession 8.0 mm, right lateral rectus resection 8.0 mm
 - One week follow-up “looks straighter”
 - One month follow-up
 - Cosmetically better but still diplopia
 - “Patient wants R enucleation”

PROGRESS

- October 2008 – July 2010
 - Ongoing complaints of troublesome diplopia
 - “only at night”
 - RET and L hypertropia, but difficult to measure due to poor fixation
 - Post-operative diplopia testing
 - Intermittent single vision at 20-25[^] BO, 8[^] BULE
 - Synoptophore assessment
 - R suppression, can't fuse
 - Trialled opaque R CL – not tolerated
 - Requesting enucleation at each visit

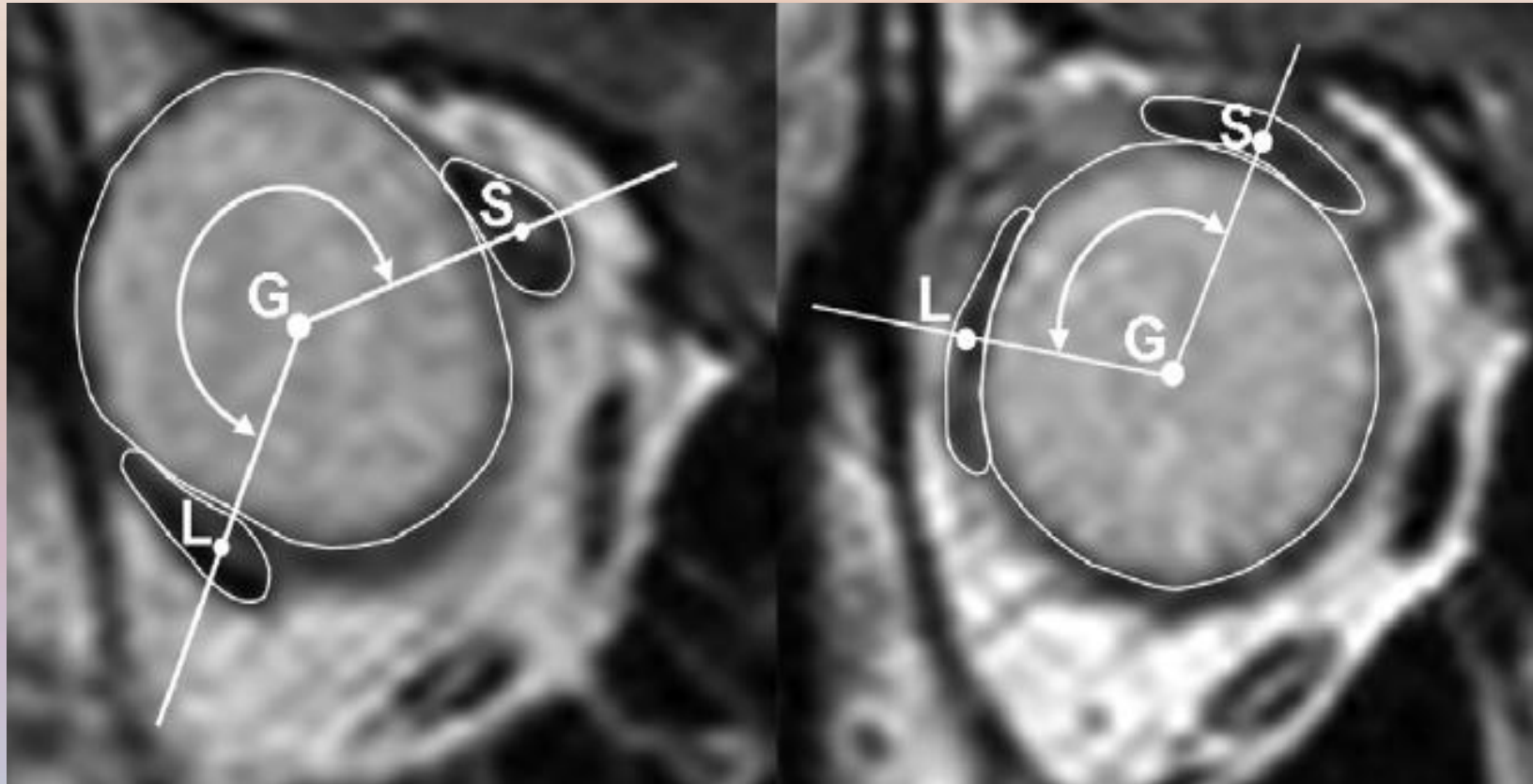
MYOPIC STRABISMUS

- Aka “heavy eye syndrome”
 - A term best avoided!
- “Acquired esotropia with high myopia (AEHM)”
 - Axial high myopia and limited ocular motility
 - Typically associated with esotropia and hypotropia of affected eye
 - Can also be exodeviation

MYOPIC STRABISMUS

- Aetiology
 - Increasing awareness of dislocation of EOM paths in this condition
 - LR displaced inferiorly
 - SR displaced superiorly
 - Hypothesis of axial elongation of globe prolapsing posterior pole out of muscle cone
 - Causing above muscle displacements

MYOPIC STRABISMUS



MYOPIC STRABISMUS

- A definition based on modern understanding
 - Average “angle of dislocation” of globe in 36 eyes with AEHM = 180 degrees
 - Average “angle of dislocation” of globe in 27 control eyes (including 9 high myopes) = 102 degrees
 - Therefore “angle of dislocation” abnormal if >110 degrees (personal communication)

MYOPIC STRABISMUS

- Treatment
 - Numerous surgical approaches
 - MR recessions, recess/resects
 - Recession of nasal conjunctiva
 - Muscle transposition (eg. superior transposition of LR insertion)
 - Limited success, early recurrences

MYOPIC STRABISMUS

Surgical Procedure for Correcting Globe Dislocation in Highly Myopic Strabismus

MAKOTO YAMAGUCHI, TSURANU YOKOYAMA, AND KUNIHICO SHIRAKI

• **PURPOSE:** To design a surgical procedure for correcting globe dislocation in strabismus in high myopia (highly myopic strabismus).

• **DESIGN:** Prospective, interventional case series.

• **METHODS:** We examined 36 eyes of 21 patients with highly myopic strabismus and 27 eyes of 27 healthy volunteers as controls at Osaka City General Hospital between 2000 and 2006. Anatomic relationships between the muscle cone and globe were analyzed using magnetic resonance imaging. Ranges of globe movement and angles of ocular deviation were measured quantitatively as angles of maximum abduction and sursumduction and angles of ocular deviation, respectively, using the Goldmann perimeter and alternate prism cover tests. A surgical procedure involving muscle union of the superior rectus and lateral rectus muscles was performed in 23 eyes of 14 patients to restore the dislocated globe back to the muscle cone.

• **RESULTS:** After surgery, the angle of dislocation of the globe, defined as the angle formed by a line connecting the area centroid of the superior rectus muscle and the globe and a line connecting area centroid of the lateral rectus muscle and globe against the supertemporal wall of the orbit, was significantly decreased ($P < .001$), and angles of maximum abduction and sursumduction and the angle of ocular deviation improved significantly ($P < .001$).

• **CONCLUSIONS:** This surgical procedure to restore the dislocated globe back into the muscle cone by uniting muscle bellies of the superior rectus and lateral rectus muscles is effective for highly myopic strabismus. (Am J Ophthalmol 2010;149:341–346. © 2010 by Elsevier Inc. All rights reserved.)

extreme condition has been called convergent strabismus fovea³ or myopic strabismus fovea.⁶ However, strabismus associated with high myopia does not always take the form of strabismus fixus. Severity varies from small-angle esotropia with mild restriction in abduction,^{6,7} in which the eye can be moved past the midline, to strabismus fixus. The strabismus is not always esotropic, with even exotropia and hypotropia reported.⁸ What these conditions have in common is axial high myopia and restrictive ocular motility. We propose the term highly myopic strabismus for this disease and use this term throughout this article.


Several reports have proposed a variety of causes for highly myopic strabismus.^{9–12} We noted 3 papers^{2,13,14} reporting inferior displacement of the lateral rectus (LR) muscle using different methods. Both Ohta and associates and Krizok and Schroeder speculated that downward displacement of the LR muscle may disturb abduction.^{13,15} However, although downward shift of the LR muscle may weaken the abducting force, this itself does not explain how both abduction and sursumduction are restricted simultaneously in this disease, particularly in strabismus fixus. Furthermore, clear explanations on how the LR muscle becomes displaced have not been provided. Traditional surgical procedures include recession or tenotomy of the medial rectus muscle, recession of the nasal conjunctiva, ordinary recession and resection procedures, and the traction suture. Although these procedures are effective in some cases, esotropia often recurs within a few months.^{6,7,16} Having noted the downward displacement of the LR muscle in this disease, some authors have reported superior transposition of the insertions of the LR muscle, the medial rectus muscle, or both¹⁴ or superior fixation of the LR muscle belly.¹⁷ With regard to dislo-

MYOPIC STRABISMUS

- “Yokoyama procedure”
 - Muscle union using a single non-absorbable suture of LR and SR, to restore the dislocated globe back into the muscle cone
 - In 23 eyes of 14 patients
 - 19 eyes combined with MR recession due to either
 - Intra-op persistence of restriction of FDT
 - Persisting esotropia post-operatively
 - Angle of dislocation 184 degrees pre-op, 100 degrees post-op
 - Angle of deviation 59 degrees pre-op, 0.7 degrees post-op

MANAGEMENT ISSUES

- How can patient be experiencing diplopia?
 - History sounds unusual
 - “only at night”
 - Poor R vision
 - RET preceded diplopia by several years
 - ?now outside suppression scotoma
 - Sensory testing belies this
- How can we make him better?
 - Inability to demonstrate fusion
 - ?patching only option
 - Is there a chance removing right cataract would help?
- Is his request for right enucleation reasonable?



CASE THREE

- 74 year old lady referred OMC December 2009
 - One year history horizontal diplopia
 - Treated with increasing power prismatic correction
 - MRI brain/orbits November 2008 showed no cause for esodeviation
- Pochx
 - Childhood LET with amblyopia
- PMHx
 - HT, Uterine Ca 1989

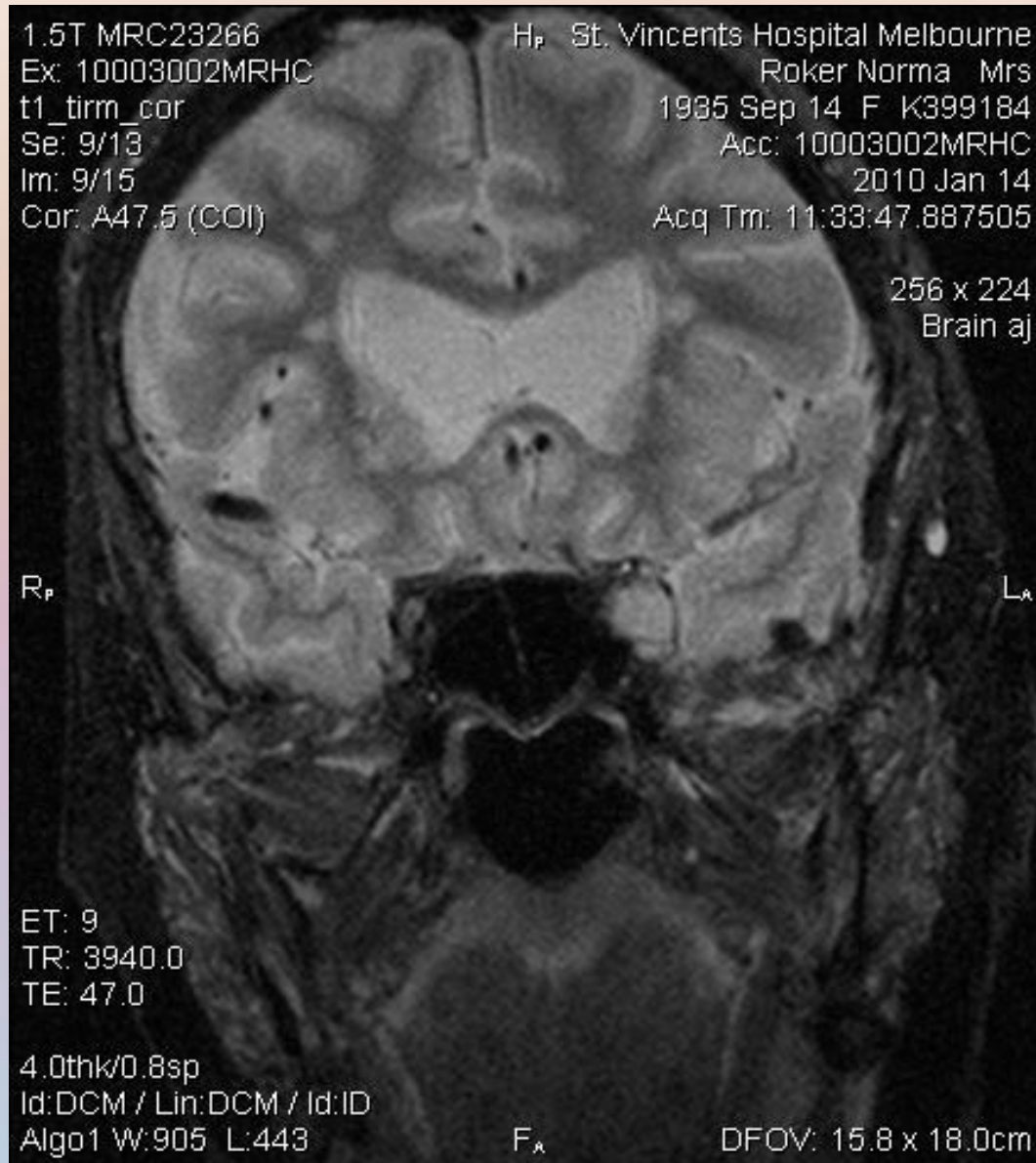EXAMINATION

- VA 6/6 R 6/36 L
 - Wearing +5.0 OU, 10[^] BO total prism
- LET 20, LET' 18
- LLR- with decreased L abducting saccades
- Interesting sensory findings
 - No diplopia at uncorrected angle
 - But diplopia produced by “No. 1” Sbisa bar
 - With prism in place, no diplopia with any filter
 - Conclusion: Prism puts patient in dense, “old” suppression scotoma, cf uncorrected angle where shallow “new” suppression scotoma

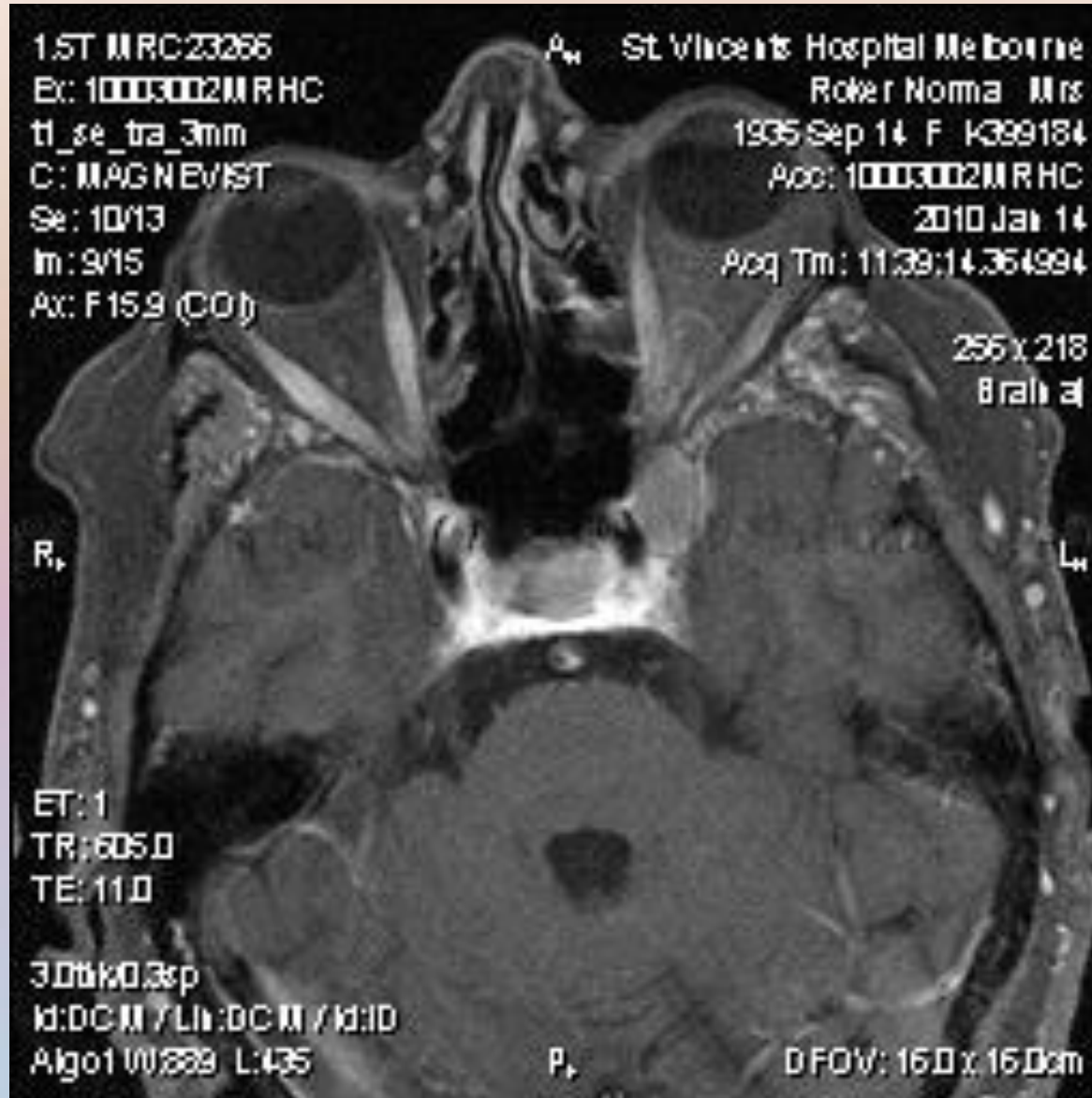INVESTIGATION

- MRI November 2008
 - Requested to investigate acute CNVI palsy
 - October 2009 – review requested
 - ?EOM enlargement
 - December 2009 – review finds no EOM enlargement
 - BUT NOTES CAVERNOUS SINUS LESION

MRI JANUARY 2010



MRI JANUARY 2010



MRI JANUARY 2010

- Expansile solid mass centred in left cavernous sinus, no extension to Meckel's cave or foramen rotundum.
- Low signal on T1 or T2, mild enhancement
- Measurements 14 x 13 x 11 mm
- Differential = meningioma or schwannoma
- UNCHANGED FROM MRI NOVEMBER 2008
- Neurosurgical review: not for intervention

ONGOING MANAGEMENT

- April 2010 OMC
 - LET 20^ RF, 30^ LF
 - LET' 10^ RF, 14^ LF
 - Moderate abducting force on force generation test
 - Synoptophore:
 - Normal retinal correspondence, fuses at angle, intermittent left suppression
 - 5u Botox injected left MR, good signal on EMG

PROGRESS

- June 2010 OMC
 - Botox gave complete L ptosis within 4 days, persisting
 - LET 40^ LF, 12^ RF
 - LE' 8^ LF, 2^ RF
- 22 July 2010 OMC
 - Good levator function
 - LET 35^ LF, 16^ RF
 - LET' 25^ LF, 14^ RF
 - Booked for L SR and IR transposition to LR insertion
 - ?for augmentation or not