

Case 2

When a routine operation doesn't go right

6 y o boy

Referred for a 2nd opinion 3w post Sx with RH.

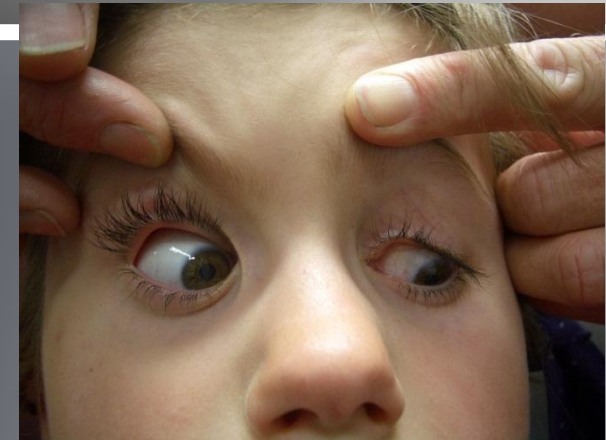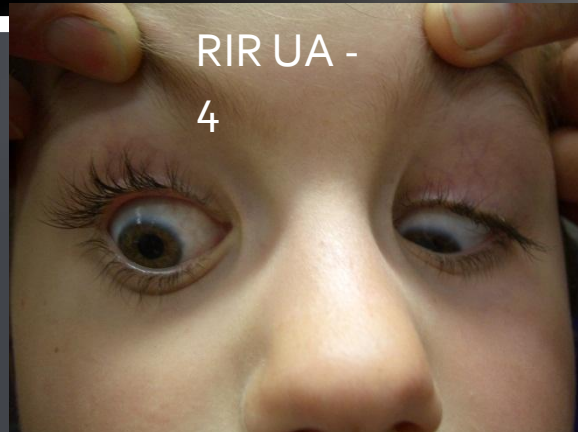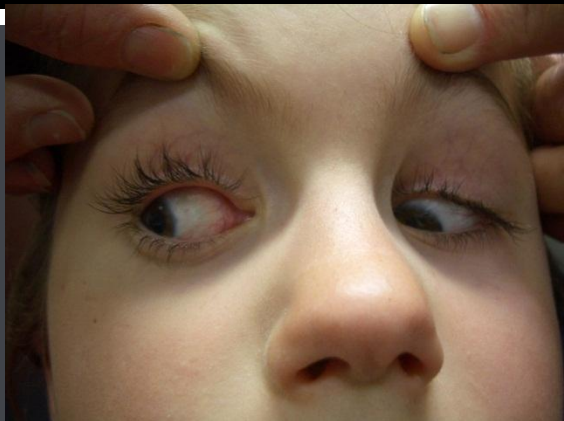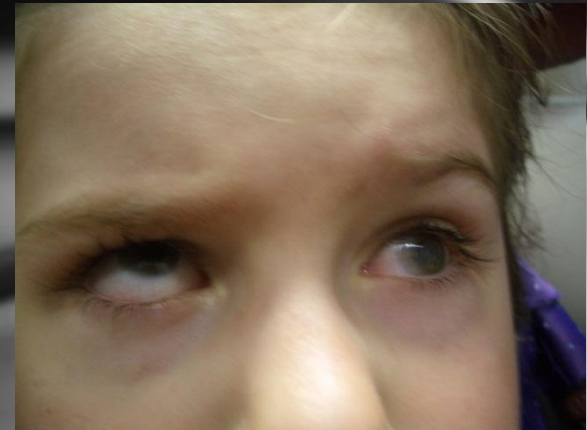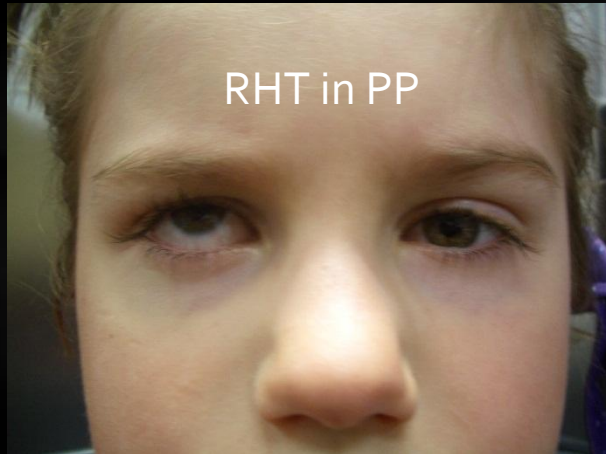
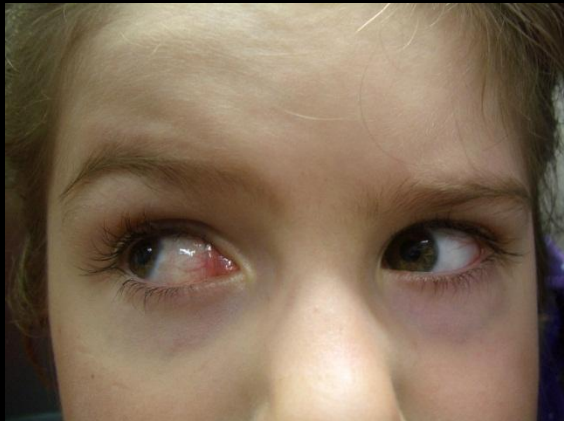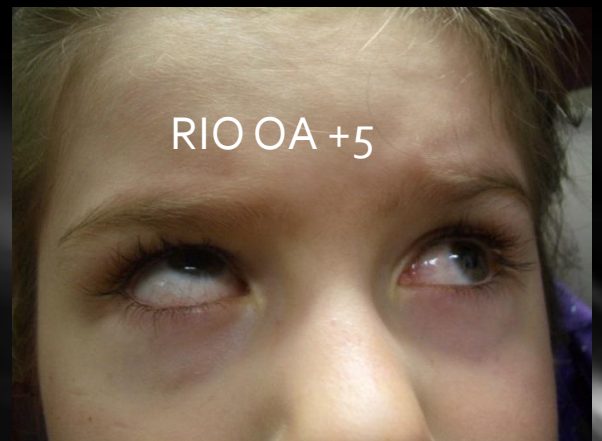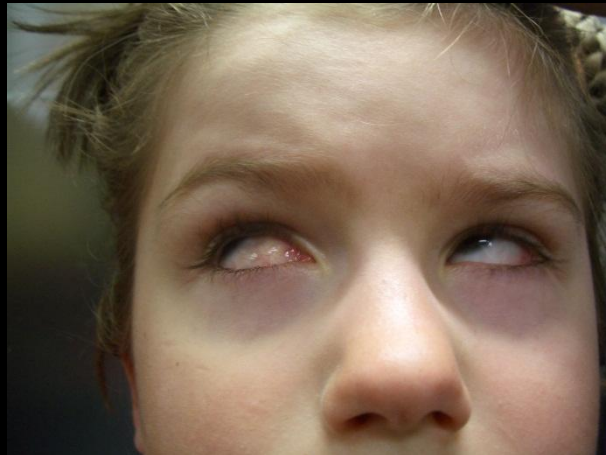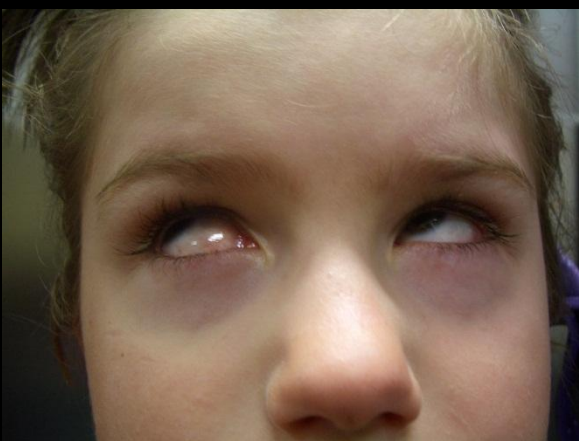“V” pattern LET since 2 y o.

Glasses: +2.50 OU (cyclo +5.00) and patch the R.

Had BMMR (5mm to 11mm from the limbus) + bil IO myectomy (22/12/2010).

On D1: RH with depression deficit greater on aBduction.

3w post-op: sl improvement of R depression, RIO OA and VA preserved.



What happened?



On Examination:

RVA 6/12cc LVA 6/9cc

Manifest refraction over current glasses:

- R +1.00 L +0.50 (sl under plused)

On UG F extorted; on DG F intorted

C-T : D RH 25 LET 16

 N RH' 30 LET' 14

AXL R 22.15mm L 21.96mm

Surgical findings (3w post 1st Sx)

Sx II:

Findings: RIO found to be normal

RIR had been disinserted and was not found.

Procedure:

RIO sutured just ant to lat edge **RIR** insertion.

The lower $\frac{1}{2}$ of the **R MR+LR** sutured to the nasal and temporal edges of the **RIR** insertion.

L LR resected

Question: Why does IO transposition and $\frac{1}{2}$ horizontal muscle transposition work?

When you have the supranuclear instruction 'look up':

SR & IO are recruited, the antagonists: IR and SO are switched off [Sherrington's law]

When you have the supranuclear instruction 'look down':

IR [& maybe] SO are recruited, SR and IO are switched off

In this case, RIR has been detached, RIO still working, LIO weakened.

When looking up --> only RSR works,

RIO now acts as an anti-elevator because:

- the neurovascular bundle of the IO now restricts upgaze*
- the insertion is now ant to the equator, and when RIO is recruited it may even pull the eye down

When looking down, RIO does nothing because it's insertion is now ant to the equator

RSR is switched off

The transposed halves of the horizontal recti act as a 'rubber band' to pull the eye down, and can only be effective because the elevators of the eye are switched off.

*Costenbader lecture. Anatomy and surgery of the inferior oblique muscle: recent findings. Stager DR.J
AAPOS. 2001 Aug;5(4):203-8

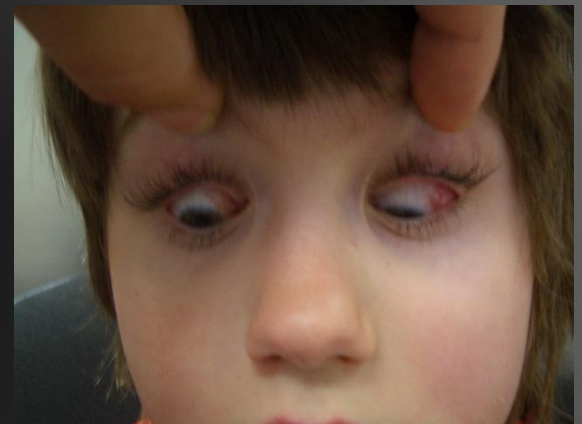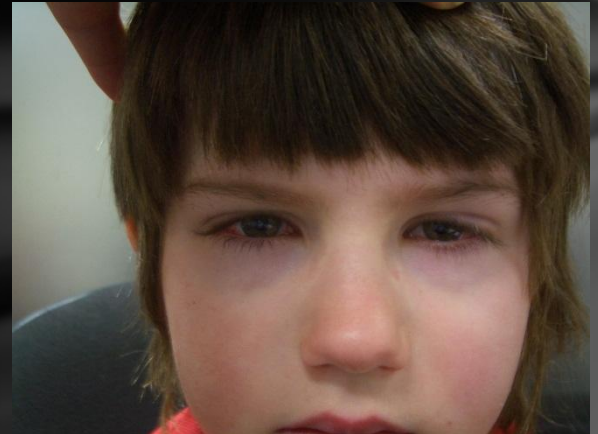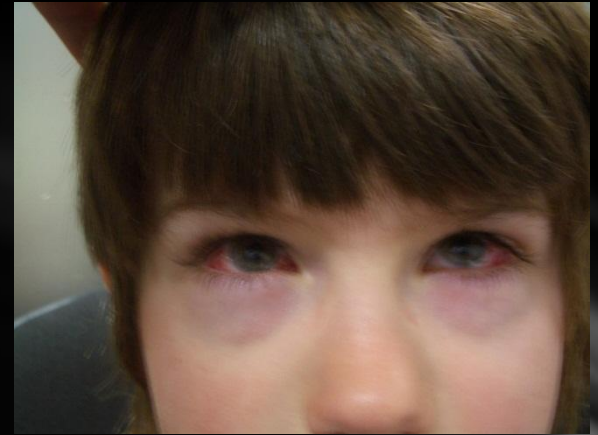3m post op:

Infrequent diplopia

Straight for D&N

DG: sl restriction (R),
sl ET on DG.

UG barely restricted



Discussion: surgical results (1)

3 pts with snapped IR (between the muscle and its tendon, 8-10mm behind the insertion) during squint Sx). Treated with Sx: a modified inverse Knapp procedure: transposition of the Inf halves of the horizontal m's to the insertion of the IRM's.

1 pt was ortho, 1-needed prisms and 1- reoperated.

1 had good infraduction, 2 limited. No anterior segment ischemia and no limitation of horizontal movements.

(1)The snapped inferior rectus. Kowal et al, Aust N Z J Ophth1998

Discussion: surgical results (2)

2 pts with ruptured IRM were Treated with modified Jensen transposition procedure : inferior transposition of the inf halves of the horizontal recti w/o disinsertion.

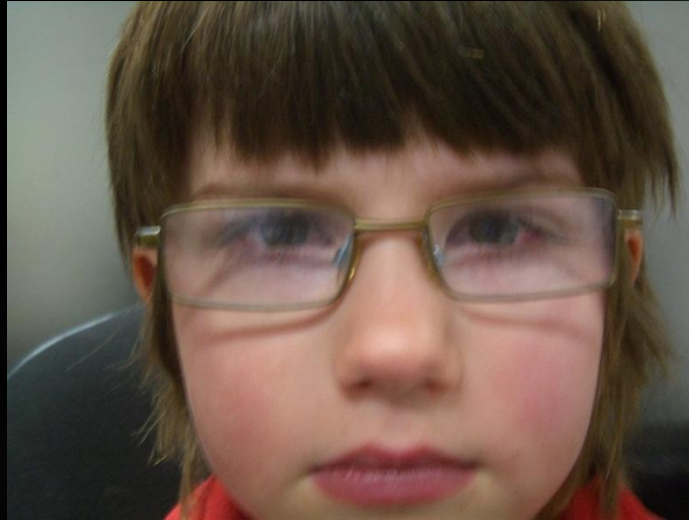Results: small overcorrection treated with prisms and reop. Both had SV in PP and 40° of depression.

Discussion: surgical results (3)

A snapped IRM during endoscopic ethmoidectomy procedure, was treated with IOM transposition with restoration of fusion in PP.

(3)Anterior transposition of the inferior oblique muscle for a snapped inferior rectus muscle following functional endoscopic sinus surgery. Aquirre-Aquino et al. Ophth Surg laser imaging 2005

In summary



Occasional squint surgeons: inferior oblique surgery is challenging.

If result is weird, re-operate quickly.

The result might have been even better if IR was found.